

Case Report | Open Access

Tumor-Induced Sensory Epilepsy: About a Case

Hakim Si AHMED¹, Smail DAOUDI¹, Hakim LEKLOU², Halim MORSLI²

¹Department of Neurology, Nedir Mohamed Teaching Hospital, Algeria

²Department of Neurology, Lamine Debaghine Teaching Hospital, Algeria

*Correspondence: Hakim Si AHMED, Department of Neurology, Nedir Mohamed Teaching Hospital, Algeria. E-mail: siahmed-hakim@hotmail.fr

Received: September 09, 2021; Accepted: September 23, 2021; Published: September 30, 2021

Copyright: © 2021 Ahmed HS, et al. This is an open-access article distributed under the terms of the Creative Commons Attribution License, which permits unrestricted use, distribution, and reproduction in any medium, provided the original author and source are credited.

INTRODUCTION

Olfactory hallucinations are part of psycho sensory hallucinations, most often associated with taste hallucinations, and especially experienced in an unpleasant manner (unpleasant odors). The causes are multiple, and the epileptic origin is rare, described for the first time by Jackson in 1899, they are related to an epileptic discharge at the internal temporal level, particularly the uncus [1] or the orbit frontal cortex. We report the observation of a patient who presented with olfactory hallucinations of epileptic origin, revealing temporal internal epilepsy in a ganglioglioma.

OBSERVATION

18-year-old patient, with no history (especially psychiatric), who has presented paroxysmal episodes for three years (lasting one minute), with a perception of

strong, unpleasant, nauseating odors, most often causing vomiting, unaccompanied contact breakage, motor automatisms, psychiatric disorders, migraine headaches. The frequency of these episodes was five episodes per day.

Psychiatric and otorhinolaryngeal examinations were unremarkable, and neurologic examination found no anosmia or other objective signs.

A routine intercritical EEG performed repeatedly and after activation (sleep deprivation and nap EEG), did not show epileptic discharges or slowing down. For this, a Video-EEG was programmed, which recorded an electro-clinical crisis made of usual olfactory hallucinations, concomitant with a flattening of the electroencephalographic tracing on the Antero-middle and left basal temporal regions, followed delta rhythmic activity of the same topography, without other clinical signs (Figure 1).

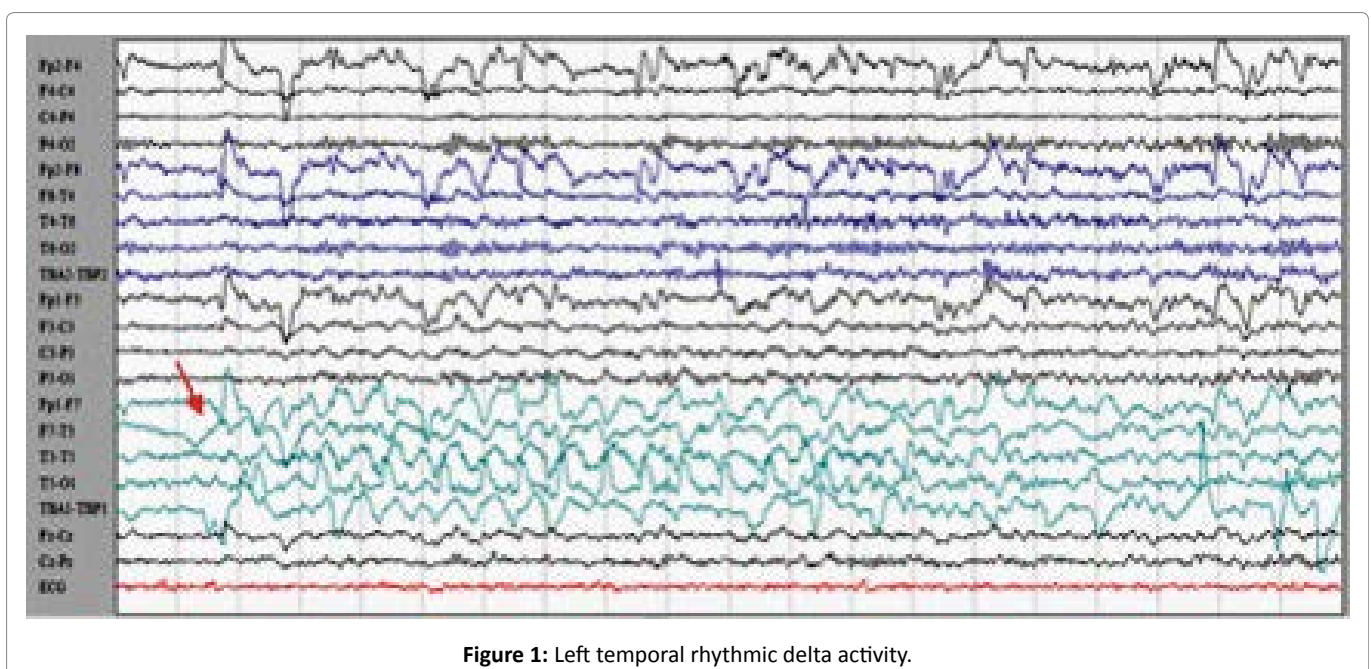


Figure 1: Left temporal rhythmic delta activity.

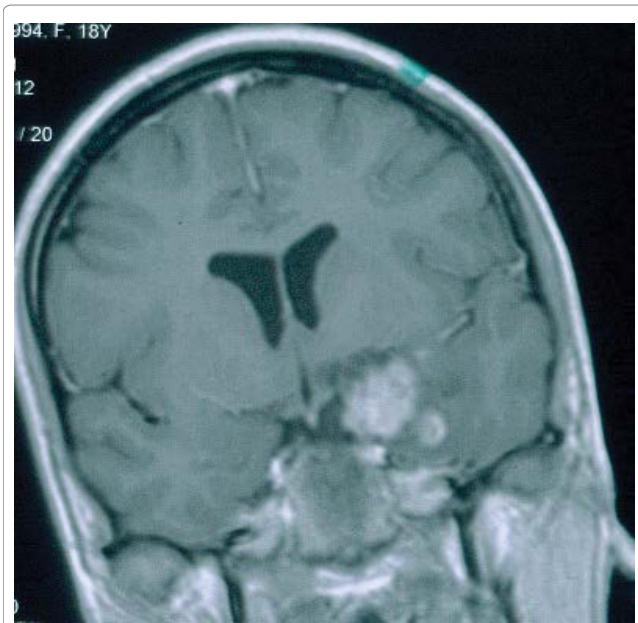


Figure 2: Left Temporo-mesial ganglioglioma, infiltrating the uncus.

Given the electrical abnormalities found on video-EEG, a brain MRI was performed which revealed a lesion in favor of a left temporomesial ganglioglioma infiltrating the uncus (Figure 2).

Overall, the electro-clinical data are in favor of partial epilepsy starting at the left internal temporal point (temporal uncus). These data are correlated with the site of the temporal ganglioglioma (infiltrating the uncus). Despite an anti-epileptic treatment (biotherapy combining Levetiracetam three-gram per day and Lamotrigine three hundred milligrams per day), the patient continued to have five seizures per day, which motivated a surgical sanction for epileptic purposes amounting to a laminectomy. After the operation, there was a total disappearance of the olfactory hallucinations with a postoperative follow-up of 24 months, and without postoperative complications.

DISCUSSION

Faced with the paroxysmal, brief, and stereotypical character of these olfactory hallucinations, the absence of psychiatric signs, migraine symptoms, and the notion of exposure to a toxicant, the hypothesis of an epileptic origin was raised, despite the normality of standard inter-critical EEGs. This situation led us to perform a

video-EEG exploration, thus making it possible to retain the diagnosis of partial temporal internal epilepsy.

The clinical manifestations of partial seizures are very varied and can sometimes be confusing, especially when the interictal EEGs are normal; this is particularly the case with epilepsies originating in the mesial (internal) parts of the temporal lobe [2]. Our observation perfectly illustrates this situation and highlights the value of a video-EEG exploration in terms of positive and differential diagnosis of epilepsies [3].

The disappearance of the olfactory hallucinations after complete resection of the tumor confirms a posteriori hypothesis put forward on the epileptic origin, and on the epileptogenic zone (left temporal internal including the uncus) of these hallucinations. Our observation thus underlines the interest in anatomy-electroclinical correlations in the pre-surgical evaluation of pharmacoresistant partial epilepsies [4-6].

CONCLUSION

Internal temporal crises are accompanied by a rich and confusing psychic semiology; this is the case with olfactory hallucinations which should lead to a discussion of an epileptic origin in order not to overlook an underlying pathology, in a particular tumor.

REFERENCES

1. Jackson J, Stewart P. Epileptic attacks with Warning sensations of smell and with lectual aura (dreamy state) in patient who had symptoms pointing to goss organic disease of the right temporo-sphenoidal lobe. *Brain.* 1899;22(11):179-207.
2. Marsan CA, Zivin LS. Factors related to the occurrence of typical paroxysmal abnormalities in the EEG records of epileptic patients. *Epilepsia.* 1970;11(4):361-381.
3. Benbadis SR, O'Neill E, Tatum WO, Heriaud L. Outcome of prolonged video-EEG monitoring at a typical referral epilepsy center. *Epilepsia.* 2004;45(9):1150-1153.
4. Franck. N, Thibaut. F, hallucinations. 2003 Editions Scientifiques et Médicales Elsevier SAS. 37-120-A-10.
5. Munari. C et Kahane. P: traitement neurochirurgical de l'épilepsie. *Epilepsy surgery/editor, Hans otto lüders- 2nd ed. Encycl Med Chir (Elsevier, Paris), 17-700-D-10, 1998, 14 p.*
6. Serratrice. G, Azulay. J.P, Serratrice. J. Olfaction et gustation. *EMC Neurologie. Paris : Elsevier, 2006. 17-003-M-10.*