

## Migratory Caterpillar Hair in the Eye: Case Report

Houssaine Ait Lhaj<sup>1\*</sup>, Youssef El Kamouni<sup>2</sup>

<sup>1</sup>Department of Ophthalmology, Hopital Militaire Avicenne, Marrakech, Morocco.

<sup>2</sup>Department of Biology, Hopital Militaire Avicenne, Marrakech, Morocco

\*Correspondence: Houssaine Ait Lhaj, Department of Ophthalmology, Hopital Militaire Avicenne, Marrakech, Morocco. Email: aithlhaj@hotmail.com

Received: May 03, 2021; Accepted: May 19, 2021; Published: May 26, 2021

Copyright: © 2021 Lhaj HA, et al. This is an open-access article distributed under the terms of the Creative Commons Attribution License, which permits unrestricted use, distribution, and reproduction in any medium, provided the original author and source are credited.

### Abstract

Caterpillars cause several ocular lesions. These will enter the eyeball and migrate to the ocular tissues leading to inflammatory reaction to the foreign body. it's a comparatively rare condition with refined findings. Here, we tend to report a case of caterpillar hair inflicting membrane abrasion and anterior inflammation in a very 13-year-old lady and its management. Also, we tend to want to spotlight the importance of shut follow up in these patients. Patient was symptomatically higher once caterpillar hair were far away from anterior section. however inferior inflammation persisted even once a pair of months of treatment. Patient was maintained on low dose steroids to forestall more increase in anterior or posterior section inflammatory response and was closely monitored for an equivalent.

**Keywords:** Migratory caterpillar hair, Ocular inflammation, Ophthalmia, membrane Abrasion.

### CASE REPORT

A 13-year-old lady bestowed with a 1-day history of foreign body sensation, redness, pain and photophobia within the Left Eye (LE). The patient gave a history of jaunt her native place and keep in a very house before the symptoms began to seem. She had then shown to a neighborhood doctor on whose recommendation she used topical antibiotics and artificial tears while not relief.

At presentation, the patient had sight of 20/20 in each eye. Examination of the left eye showed min lid lump and marked mucous membrane congestion of each palpebral and conjunctiva. elaborate slit lamp examination discovered multiple, black, linear foreign bodies connotative caterpillar hairs, that were diffusely adorned within the lower and higher tarsal mucosa and sub- conjunctival penetrated within the inferior neural structure conjunctiva.

There was one hair partly penetrating peripheral anterior tissue layer at half-dozen o'clock, one intra-stromal hair

within the midperiphery at four o'clock and one hair at the half-dozen o'clock within the anterior chamber partly penetrated within the posterior membrane stroma.

Cornea had superficial animal tissue defects in a very crisscross pattern. The anterior chamber showed 2+ cells. The lens was clear, and no abnormalities detected on fundoscopy in vitreous and membrane. the correct eye examination was traditional.

The UBM and B scan confirmed clinical findings and failed to reveal from now on intraocular hair.

Superficial hair on the conjunctiva and the tissue layer was removed underneath sterile precautions mistreatment fine extractor, on the slit-lamp. The patient was started on Lubricants (carboxy alkyl polyose zero.5%) half-dozen times, topical antibiotic (moxifloxacin zero.5%) four times, homatropine a pair of eye drop three times and low dose steroid eye drops (prednisolone acetate ophthalmic suspension 1%) half-dozen times (Figure 1).

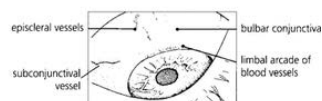
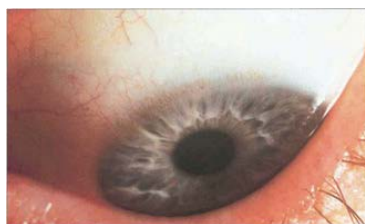
Figure 1: Slit-lamp image of caterpillar.

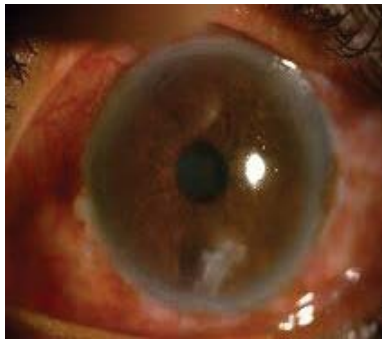


Figure 2: Slit lamp image of intraocular penetration.

After an entire exercise the patient was then admitted for the surgical removal of intracameral hair underneath anesthesia to avoid ophthalmic reactions. elaborate examination of the anterior section was performed underneath magnifier to rule out presence of from now on hairs. The intrastromal membrane and subconjunctival hairs weren't touched to avoid scarring thanks to exploration (Figure 2).

Post operatively patient was discharged on low dose topical steroids, lubricants and antibiotic eye drop. Patient showed vital improvement throughout the follow up visits however wasn't fully freed from inflammation. once a month of follow up she is currently maintained on low dose topical steroid eye drop and underneath regular follow up to stay a check on intraocular inflammation.

## DISCUSSION

Caterpillar hair could penetrate the attention (the mucosa or cornea) forcibly by direct contact or by being rubbed. Their presence within the mucous membrane sac causes intense pain.

Caterpillar hair (setae) is sharp and fine with unifacial barbs thanks to that they will migrate towards the bottom. The hair is brittle and fracture simply once they need penetrated the attention. they need the power to travel within the eye, maybe due to the form of the hair and stresses from the lid and ocular movements, or perhaps presumably from vascular pulsations [6].

Pathologically, there will be Associate in Nursing acute inflammation followed by a tumour reaction round the hair. The intensity of the reaction and the result most likely depends upon the amount of hair or the number of foreign materials coming into the attention [7,8].

First part is with severe symptoms once the patient presents to the OPD. Thereafter, there's a quiet interval lasting for some days, that is outwardly the amount

throughout that hair migrates through the tissue layer. it's followed by a part of inflammation once the hair is free or sticking within the AC or is irritating the anterior anatomical structure. Sometimes, this reaction is also sufficiently severe to provide a hypopyon and nodules on the iris or flat yellow and oval nodules within the mucosa. Some eyes of conjunctivitis nodosa could develop white plague [8].

The principal management is within the kind of thorough examination and sos removal of hair with an everyday follow up. Intraocular penetration of setae inflicting severe anterior section reaction typically responds to topical steroids and cycloplegic medication. Vitritis could need intravitreal or general steroids.

Gupta and Hari Gopal rumored the primary case of caterpillar hair involvement of the attention from North Asian country [9]. In their case, there have been caterpillar hair within the tissue layer with encompassing infiltration and far hair within the palpebral mucosa. almost like our case, most of the hair was removed except few that were lying deep within the tissue layer.

A study by Sengupta [10] rumored that the presence of deep intracorneal hair was found to be the sole risk issue for intraocular penetration. The diagnosing of caterpillar-hair was clinical in our case, as we tend to may make sure the retrieved hair underneath a magnifier. In several cases, direct history of exposure to caterpillar hair might not be out there [10]. higher lid eversion to look for preserved setae and removal of any mucous membrane or iris nodules is necessary.

## CONCLUSIONS

- Conjunctivitis nodosa could be a comparatively rare condition with refined findings, which may be lost, inflicting substantial discomfort to the patient.
- Caterpillar hairs are notable to migrate intraocularly through the membrane and cause inflammatory reaction within the eye. The prognosis is comparatively sensible even with intraocular penetration of the hair if treated in time.
- The removal of intraocular hair once analyzing the risks and edges is preferred. Such cases ought to be followed closely as late migration and late worsening has additionally been reportable in a number of these cases.
- There are reports of intraocular setae while not resulting reactivation.

- Despite the grave vary of potentialities within the manifestations, the result in most of the cases is satisfactory, if diagnosed early and treated fitly.

## ACKNOWLEDGMENT

None.

## REFERENCES

1. Ascher KW. Mechanism of locomotion observed on caterpillar hairs. Br J Ophthalmol. 1968;52:210.
2. Bishop JW, Morton MR. Caterpillar-hair keratoconjunctivitis. Am J Ophthalmol. 1967;64:778-779.
3. Bettelheim H. Penetration and migrating of caterpillar hairs into conjunctiva and cornea. Wien Klin Wochenschr. 1968;80:548-550.
4. Horng CT, Chou PI, Liang JB. Caterpillar setae in the deep cornea and anterior chamber. Am J Ophthalmol. 2000;129:384-385.
5. Sengupta S, Reddy PR, Gyatsho J, Ravindran DR, Krishna T, Vaidee V. Risk factors for intraocular penetration of caterpillar hair in Ophthalmia Nodosa: a retrospective analysis. Ind J Ophthalmol. 2010;58:540-543.
6. Gupta JS, Gopal H. Migratory Caterpillar Hairs: A Case Report and Review of Literature. Orient Arch. Ophth. 1968;6:306-307.
7. Watson PG, Sevel D. Ophthalmia nodosa. Br J Ophthalmol. 1966;50:209-217.
8. Ibarra MS, Orlin SE, Saran BR. Intraocular caterpillar setae without subsequent vitritis or iridocyclitis. Am J Ophthalmol. 2002;134:118-120.
9. Bhende M, Biswas J, Sharma T. Ultrasound biomicroscopy in the diagnosis and management of pars planitis caused by caterpillar hairs. Am J Ophthalmol. 2000;130:125-126.
10. Sengupta S. Risk factors for intraocular penetration of caterpillar hair in Ophthalmia Nodosa: A retrospective analysis. Indian J Ophthalmol. 2010; 58(6):540-543.